

Measurement of whole spine sagittal alignment using the SLOT radiography of the SONIALVISION safire series clinical application



Kenji Endo, M.D.

Department of Orthopaedic Surgery, Tokyo Medical University Hospital¹

Department of Radiology, Tokyo Medical University Hospital²

Kenji Endo¹, Koichi Numajiri², Toshio Hasome², Yasuo Tsuruta², Nobuo Ishigami², Yoshikazu Iwasaki², Sayaka Komura², Kei Hoshikawa², Chiharu Ide², Rei Ohshima², Yusuke Uchida², Mitsuru Watanabe², Shinya Hyuga²

1. Introduction

Whole spine radiography is often required for the diagnosis of conditions such as scoliosis and kyphosis; however, conventional radiography entails exposure to high-dose radiation, and image quality is often poor. Such problems are resolved with SLOT radiography, which we use as replacement for the computed radiography (CR) system using cassettes. Currently, an average of 50 SLOT-radiography per month is being performed at our hospital.

Spinopelvic alignment, which is affected by aging, degenerative spine and hip joint disorders, and it is also reported that it effects on low back pain, has been discussed in many medical facilities in recent years. Furthermore, since the alignment changes during walking, conventional static radiography in standing position alone was not adequate for treatment of impaired walking associated with spinal deformity. We report the evaluation of sagittal spinopelvic alignment of whole spine images which were obtained by SLOT radiography.

2. Measurement of the whole spine sagittal alignment in the intermediate standing position

Whole spine lateral images were obtained with the patient in the intermediate standing position (intermediate position) and in the natural step forward (walking position) position. Then, the following parameters were measured (Fig. 2, 3, and 4). Radiography in the intermediate standing position has been specifically reported by Suzuki et al.^{1), 2)}.



Fig. 2

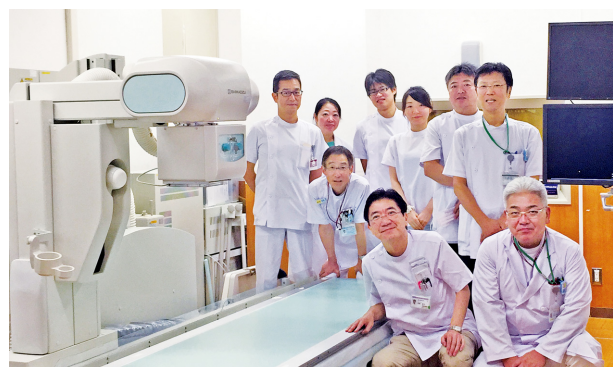


Fig. 1

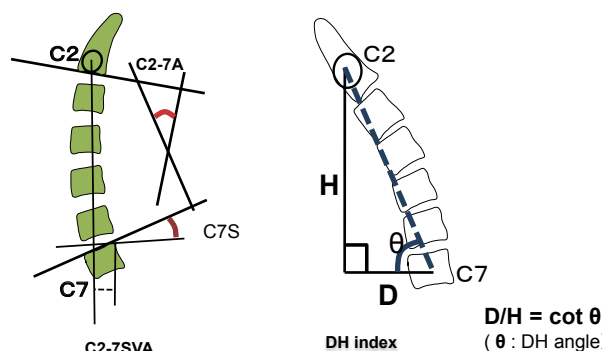


Fig. 3

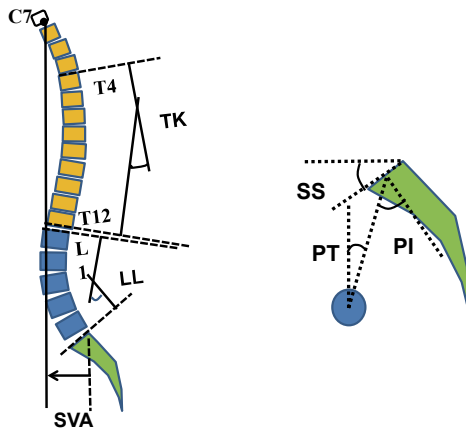


Fig. 4

1) Sagittal vertical axis (SVA)

The SVA is an important index of sagittal balance of the trunk. It is measured as the distance from the plumb line from the center of the C7 (C7PL) to the posterior edge of the upper sacral endplate surface. The thoracolumbar spine alignment has a compensatory function that helps to minimize deflections of the SVA. However, the SVA tends to gradually tilt forward with aging. Forward SVA tilt beyond the hip joint is referred to as the positive imbalance (Fig. 5).

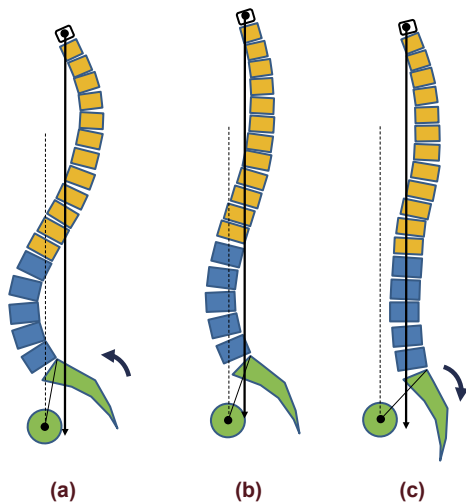


Fig. 5 Compensatory sagittal plane balance

2) C2-7 angle

This factor is used to evaluate the degree of cervical lordosis. This is the angle between the inferior and superior endplates of the spine of the C2 and the C7, respectively. It is stated that the cervical spine curvature is highly correlated with the C7 slope.

3) C7 Slope angle (C7S)

This angle is used to evaluate the slope at the base of the cervical spine. The angle is formed between a horizontal line and the superior endplate surface of the C7 which has positive correlation with cervical lordosis and thoracic kyphosis.

4) Thoracic kyphosis (TK)

The TK is measured as the angle between the superior endplate surface of the T1 and inferior endplate surface of the T12^{6), 7)} (Fig. 4). Since the T1 is sometimes unable to identify due to overlapping with shoulder joints, TK may be measured between the superior endplate surface of the T4 and the inferior endplate surface of the T12. This angle tends to increase with aging.

5) Lumbar lordotic angle (LL)

Since the focal L5-S1 lordosis accounts approximately 30% of the lumbar lordosis, the LL is measured between L1 and S1.

6) Sacral slope (SS)

This is the angle between a horizontal line and the slope of the superior sacral endplate surface. The SS shows a positive correlation with the LL, and a negative correlation with the pelvic tilt.

7) Pelvic tilt (PT)

The PT is used to evaluate the degree of pelvic rotation. This is the angle between the upper plumb line from the femur head center and the center point of the superior sacrum endplate surface. Normally, forward pelvic rotation is referred to as anterior pelvic tilt, and rearward rotation as posterior pelvic tilt.

8) Pelvic incidence (PI)

The PI indicates the degree of sacral tilt with respect to the pelvis. The PI is individual intrinsic parameter which is not affected by postures. The body shape around pelvis will vary according to the degree of the PI (Fig. 6). The PI also correlates with the PT and the LL and may indicate the onset of spondylolisthesis or other conditions. Consequently, its importance is being increasingly recognized in recent years. Recent researches have been based on the PI, the angle formed between the perpendicular line to the center point of the superior sacrum endplate surface and the line connecting from the said center point to the center of the femur head, and the mathematical relationship among PI, PT and SS is expressed as $PI = SS + PT$.

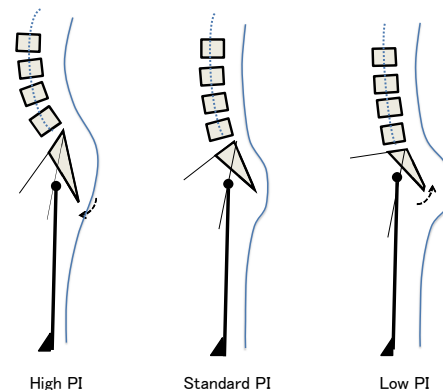


Fig. 6

Table 1

	SVA	TK	LL	SS	PT	PI
Mean (mean±SD)	0.6±2.6	40.2±11.9	53.6±9.9	35.3±6.4	10.8±5.5 (PT)	46.7±8.7 (PI)
Reference value	-2.3~3.0	16.4~64.0	33.8~73.4	22.6~48.1	-0.2~21.9 (PT)	29.4~64.1 (PI)

3. Reference values for the sagittal spinal alignment

The measured reference values are shown in **Table 1**. In terms of gender discrepancy in spinopelvic alignment, a study conducted by Vialle et al.²⁾ with 300 asymptomatic volunteers showed that females had more LL and higher SS and PI values than males. However, some reports describe no significant difference was observed between genders. In our own studies, large standard deviations was found in respective parameters and no statistically significant differences. Presumably, this is due to larger variations between individuals than those between genders in the case of Japanese. In addition, in terms of sagittal alignment, Japanese tend to have lesser degree of thoracic kyphosis and lumbar lordosis, and their sagittal balance point is positioned farther forward than Caucasians. Another reports also indicate that Japanese tend to have smaller PI values and larger SS than Caucasians.³⁾

The changes in alignment with aging

The sagittal alignment in the elderly is characterized by a decrease in spinal mobility, a decrease in compensatory balance reactions, and deformity of knee and hip joints (**Fig. 7**). In terms of posture, the TK and cervical lordosis tend to increase, the LL tends to decrease, and the PT rearwards. In spines with low deformation levels, pelvic and lumbar morphology rarely causes changes in the thoracic alignment that affect cervical tilt; however, thoracic, lumbar, and pelvic morphology due to reduced spinal mobility can affect the cervical spine, which can lead to not only lumbar disorders but also cervical spondylosis.

4. Measurement of whole spine sagittal alignment in walking position

In young adults, walking motion is normally observed on hip joints and below, with only a slight amount of fore-aft pelvic rotation involved. However, in the whole spine sagittal alignment of the elderly, the pelvis and thoracic spine tilt forward during walking with an increase in C2-7 SVA and SVA. The walking angle and age have also been shown to have a negative correlation with standing SVA and a positive correlation with differences in SVA. However, changes in the whole spine sagittal alignment in the elderly during walking are not uniform. The large SVA in intermediate position of the elderly (especially in female) cause a decrease in walking width, rearward pelvic tilt, or rearward SVA shift during walking. These results differed from past reports based on treadmill studies. Normally when the elderly walk, the SVA elongates prominently, the TK increases, and the PT forwards. This is considered to be due to changes associated with forward propulsion, with the pelvis shown to rotate forward and rearward with walking rhythm. Spinal imbalance during walking with kyphosis occurs due to a decrease in walking width and compensation by the thoracic spine and pelvis. The failure of this process is considered to be the cause of impaired walking.

The effects on hip and knee joints

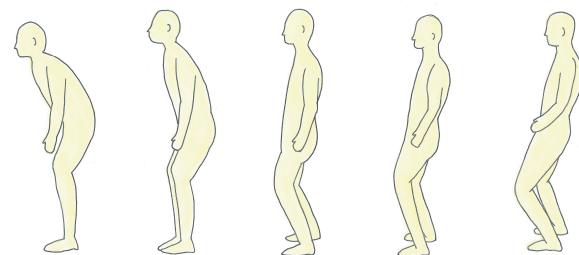


Fig. 7 In some cases, even if tilted forward in the intermediate position, the SVA decreased during walking due to compensation by pelvis and lower limbs.

5. Summary

This article describes the measurement of whole spine sagittal alignment using the SLOT radiography (Fig. 8). The SLOT radiography is a superior alternative to conventional methods due to the lower X-ray exposure dose and less image distortion.

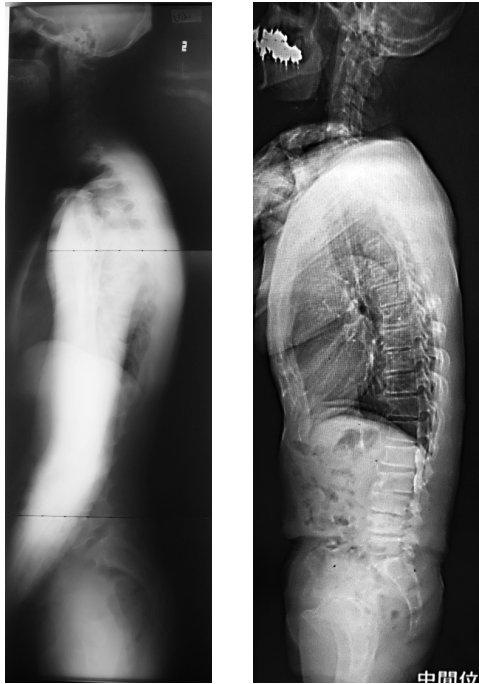


Fig. 8 Left: Conventional radiography; Right: The SLOT radiography

References:

- 1) Suzuki H et al.: Clapsed position for measurement of sagittal spinal alignment., *Eur Spine J* 19:782-786, 2010.
- 2) Faro FD et al.: Evaluation of a functional position for lateral radiograph acquisition in adolescent idiopathic scoliosis., *Spine* 29: 2284- 2289, 2004.
- 3) Endo K, et al.: *Diagnostic Imaging of Spinal Deformities*, MB Orthop, 2012.
- 4) Endo K. et al.: Characteristics of sagittal spino-pelvic alignment in Japanese young adults, *Asian Spine J*, 2014.
- 5) Kanemura T, *et al.* Sagittal spino-pelvic alignment in an asymptomatic Japanese population: Comparison of western population, *J. Spine Res.* 2:52-58, 2011.
- 6) Roussouly P et al.: plane deformity: an overview of interpretation and management, *Eur Spine J.*19: 1824-1836, 2010.